

## A 35-year-old Hemophiliac with Pseudotumor of the Thigh

Michelle O. Panganiban,<sup>1</sup> Mae N. Ramirez<sup>2</sup>, Rosally P. Zamora,<sup>2</sup> Ivy Mae S. Escasa,<sup>2</sup>  
 Agnes D. Mejia<sup>2</sup> and Ariel M. Vergel de Dios<sup>3</sup>

<sup>1</sup>Department of Family and Community Medicine, College of Medicine and Philippine General Hospital, University of the Philippines Manila

<sup>2</sup>Department of Medicine, College of Medicine and Philippine General Hospital, University of the Philippines Manila

<sup>3</sup>Department of Pathology, College of Medicine, University of the Philippines Manila

### Presentation of the Case

Our patient is a 35-year-old Filipino man, diagnosed with Hemophilia A since birth, who presented with an enlarged right thigh with multiple masses. This paper will discuss the following issues: 1) how to differentiate pseudotumor from primary bone malignancy and 2) to describe how patients with hemophilia should be prepared for surgery.

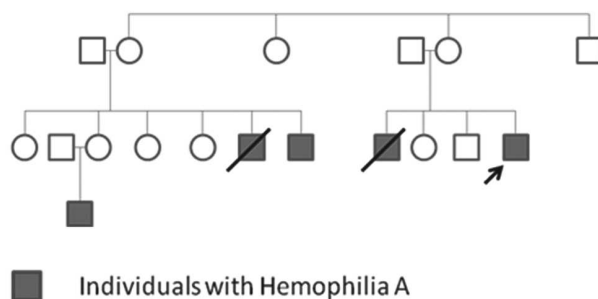
History started twelve years ago, at age 23, when he sustained multiple hematomas in a fraternity hazing. He was admitted several times for blood transfusions. He then developed an enlarging right anterolateral thigh mass about 3 x 3 cm, soft, painless, and slightly movable. No consult was done despite an increase in the size of the thigh mass.

Five years before admission, the patient noted a rapid swelling of his thigh mass after moving heavy furniture. The weakness of the leg made it difficult for him to do his activities of daily living. After two weeks, he sought consult in Philippine General Hospital. The right thigh mass measured 37 cm in its widest diameter. A fracture in the right femur was also noted. He was transfused with 50 bags of cryoprecipitate and three bags of red blood cells. Fiber glass cement was applied to the patient's right thigh, after which he was discharged with crutches. He had regular check-ups for four months with the Hematology Clinic and Rehabilitation Medicine. However, no subsequent follow-ups were done.

Three weeks before admission, the patient experienced sudden onset of pain over his right thigh, relieved with mefenamic acid. The mass grew to approximately 25 x 30 cm in diameter, followed by appearance of new masses: a 6 x 10 cm mass located medial to the first mass and a 12 x 10 cm mass over the lateral aspect of his right thigh. He reported episodes of high-grade fever associated with anorexia, vomiting, epigastric pain, easy fatigability, and melena. He

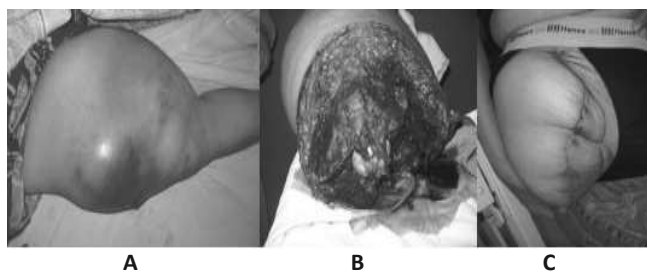
took trimethoprim-sulfamethoxazole, providing relief. However, the persistence of pain in the right thigh and a generalized feeling of body weakness prompted him to seek consult.

The patient is single and has always lived in Pasay City. He is a high school graduate and was employed as a production worker. He has no allergies, does not smoke, and rarely drank alcohol. His eldest brother died at the age of 32 and was also diagnosed with Hemophilia A. He also confirmed that he has several cousins on his mother's side who were also diagnosed with hemophilia (Figure 1).



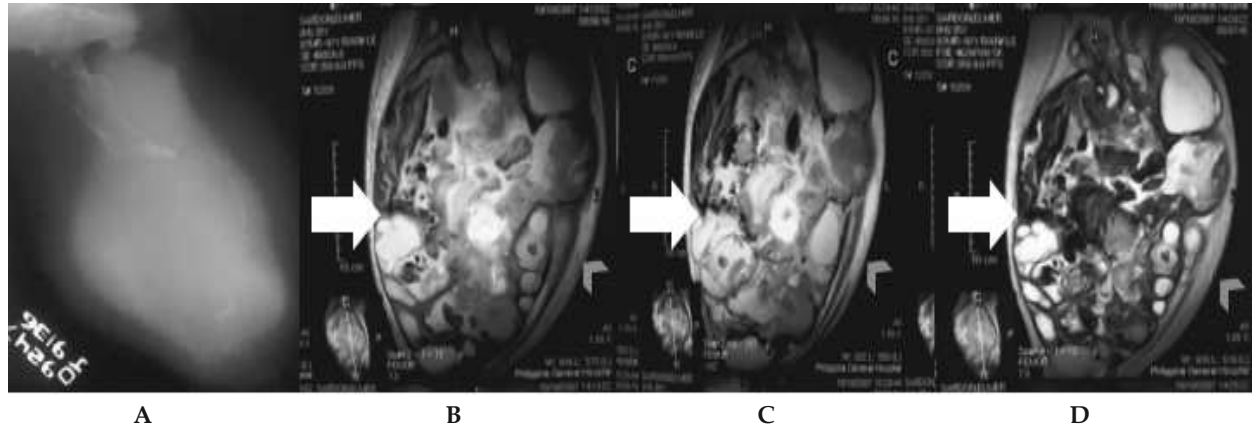
**Figure 1.** Genogram of the patient (arrow) showing members of his family known to have hemophilia.

Upon admission, physical examination confirmed a markedly enlarged and deformed right thigh with numerous pliable masses occupying two-thirds of it, with the largest circumference measuring 74 cm (Figure 2A). Bluish discoloration of the skin was noted. There were also



**Figure 2.** Photographs show the distorted right thigh with violaceous discoloration of the skin prior to operation (A), the gross specimen after the surgery (B), and right limb post-disarticulation (C).

Corresponding author: Agnes D. Mejia, MD  
 Department of Medicine  
 Philippine General Hospital  
 Taft Avenue, Ermita, Manila, Philippines 1000  
 Telephone: +632 5548400 local 2200/2206  
 Telefax: +632 5264372  
 Email: agnesmejiamd@yahoo.com

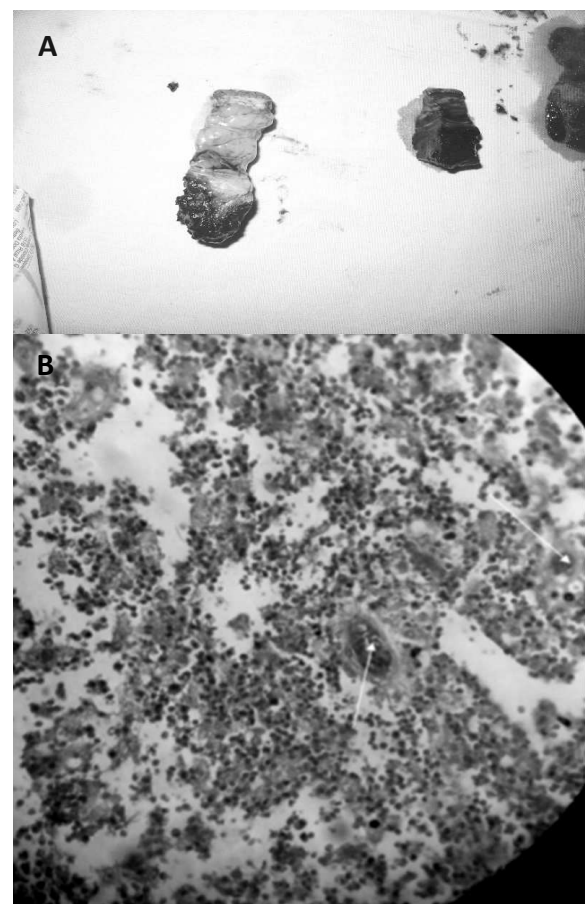


**Figure 3.** Radiograph image of the right thigh showing lysis of the middle to distal two thirds of the femur with note of a large soft tissue mass that appeared to be extrasosseous, extending from the lateral to the medial aspect (A). Sagittal MRI view in T1 (B), contrast (C) and T2 (D) weighted images show a femur converted into a heterogenous mass (white arrow), with areas of high and low density representing blood products in various stages of evolution. Atrophic muscle with hemorrhage (arrow head).

crepitations noted over the right knee. Except for pallor, the remainder of the examination was essentially normal.

The patient was started on ampicillin-sulbactam for the infected thigh mass, and later on was changed to ceftazidime and clindamycin when a new mass with a cutaneous tract developed. Laboratory findings revealed anemia and leukocytosis with neutrophilic predominance (Table 1). He was transfused with a total of 11 units of packed red cells, 20 fresh frozen plasma, and 6 bags of cryoprecipitate. Radiographs of the right knee and right thigh confirmed the following findings (Figure 3A): presence of primary bone tumor with aggressive features, and hemarthrosis of the right knee. Magnetic resonance imaging (MRI) of the pelvis, hips and right thigh revealed a large, heterogeneous, minimally enhancing mass involving the distal two thirds of the right femur measuring approximately 24.4 x 21.7 x 16.3 cm, with a multi-septated cystic component and intermixed dark signals on all sequences (Figures 3B, 3C and 3D). These findings were consistent with the following entities: a pseudotumor with repeated hemorrhage, an aneurysmal bone cyst, or a round cell tumor. Biopsy was contemplated but not done since malignancy and pseudotumor would have the same management. Hence, hip disarticulation was done instead.

Factor VIII level was determined prior to operation to determine the actual amount of clotting factor needed to be infused. The required FVIII was computed based on the patient's weight. A day prior to the operation, 3000 units of FVIII concentrate were given. Two hours after the infusion, the factor level went up to 186%. Then the FVIII concentrate was continuously infused, given at 1500 units every eight hours for two days, then 1500 units every twelve hours for two weeks. In time, the patient underwent right hip



**Figure 4.** (A) shows the specimen sent for histopathology. (B) shows an arteriole with blood clots surrounded by neutrophils and lymphocytes (arrow), indicating that inflammation and hemorrhage are present in this area.

**Table 1.** Laboratory results during the course of the patient's hospital stay.

Variable	Reference range	Admission						
		Day 1	Day 7	Day 19	Day 26	Day 61	Day 62	Day 65
Hematocrit	37-40 %	15	30	32	19	24	29	29
Hemoglobin	120-130 g/L	46	96	104	63	84	92	97
Platelet count	150-450 × 10 <sup>9</sup> /L	613	279	440	328	403	320	386
MCV	80-100fL	86.4	87	84.9	84.5		90.6	88.5
Retic (%)								
Prothrombin time (sec)	12-15	13					11.4	11.4
Partial-thromboplastin time (sec)	35.5-38	135.4	63.2				38.4	41.6
Factor VIII assay	77%				1%	186%		
Glucose	4.1-6.1 mmol/L	3.4						
BUN	3.2-8.0 mmol/L	6.28						
Creatinine	53-115 umol/L	103					44	
Sodium	140-148 mmol/L	143					143	
Potassium	3.6-5.2 mmol/L	3.6					4.4	

disarticulation. Histological examination of the right thigh confirmed the presence of organized blood clot with granulation tissue (Figure 4B). There was dystrophic calcification of the tendon and soft tissue. No malignant abnormality was noted and lymph nodes were reactive. The patient had unremarkable post-op course. FVIII transfusion was discontinued two weeks after the operation and the wound healed without complications (Figure 2C). The patient underwent rehabilitation and was eventually discharged.

### Discussion

Hemophilia A is an X-linked recessive condition due to a deficiency or absence of Factor VIII. The defect has been localized in the long arm of the X chromosome in band q28. Genetic abnormalities include genetic deletions of variable size, abnormalities with stop codon, and frame-shift defects (Figure 5).

This case has been exceptionally challenging to us because of the scarcity of resources and the rarity of the condition. Hence, this section will focus on the following objectives: 1) to discuss the differential diagnosis for the thigh mass; 2) to review the literature on pseudotumor; and 3) to discuss the perioperative management for hemophiliacs.

#### Primary bone tumor vs. Pseudotumor

We considered two differential diagnoses for the masses: primary bone tumor and pseudotumor. Table 2 summarizes the clinical features differentiating the two, while Table 3 summarizes the pathological differences. Primary bone malignancy has an unknown etiology. Patients usually complain of pain, worse at night. Examples of primary bone malignancies are osteosarcoma and round cell tumor. In contrast, pseudotumor occurs in patients with hemophilia A, and develops over several years without any symptom and is usually preceded by trauma. The heterogeneous appearance of the mass in the patient's thigh argues against the diagnosis of a tumor, since round cell

tumor would present as a multilocular, solid enhancing component with well defined borders, while sarcoma would present as a unilocular solid enhancing mass with infiltrative features. Bleeding is common in round cell tumors seen as hematomas in MRI. However, in round cell tumors, the hematoma would show homogenous age, whereas the hematomas in pseudotumor would show varying ages as a result of repeated bleeding.

**Table 2.** Clinical features differentiating primary bone malignancy from pseudotumor.

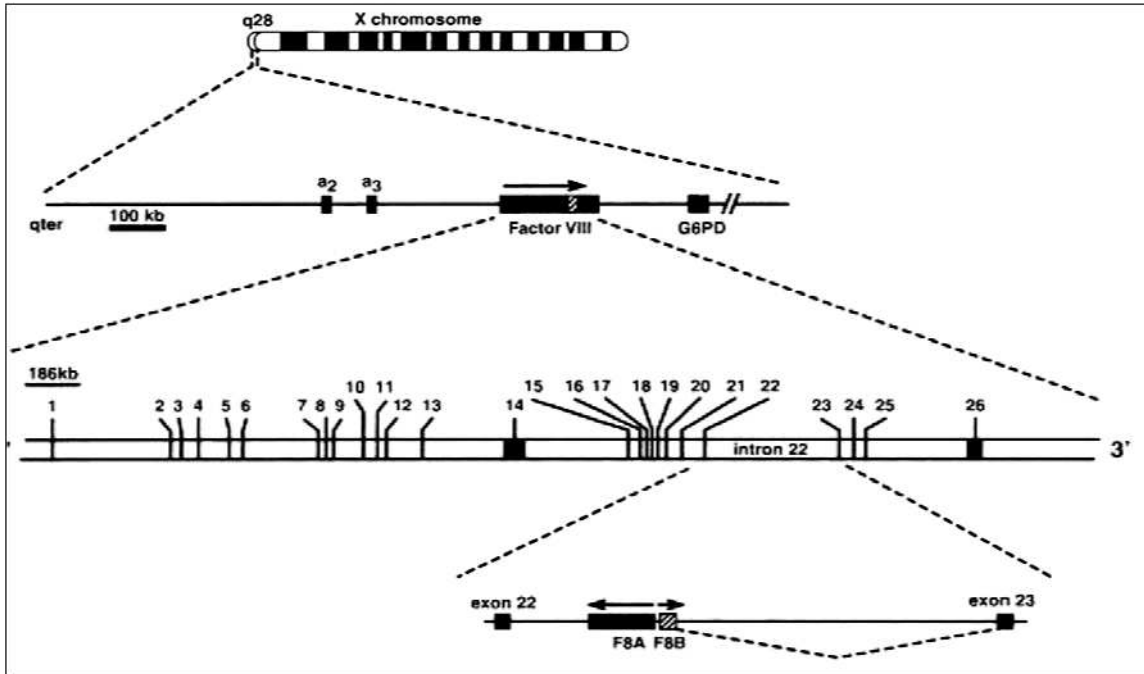
Characteristics	Primary Bone Malignancy	Pseudotumor
Etiology	Not known	History of trauma that develops over several years
Population	Occurs between 10-30 years of age	Patients with hemophilia
Clinical manifestation	Pain is more prominent	Usually asymptomatic
Sites usually affected	Distal femur>proximal tibia> Proximal humerus	Thigh and buttocks

Aneurysmal bone cyst is also a differential diagnosis. This condition will present as a multilocular cyst with well-defined borders, just like pseudotumors. However, this is not prone to recurrent bleeding episodes.

Infection could also produce an inflammatory mass in the thigh. An MRI would demonstrate a poorly marginated hyperechoic signal usually suggestive of an abscess, which was not found in this case. Our patient had a superimposed soft tissue infection.

#### Clinical Diagnosis: Pseudotumor, Right Thigh

Pseudotumor is a serious condition exclusive to hemophilia. It arises from a collection of blood in the soft tissues and bones forming cysts, leading to the destruction of



**Figure 5.** Diagram of the location of factor VIII gene in q28 on the X chromosome. (Adapted from Lichtman MA, et. al, *Williams Hematology*, 7<sup>th</sup> Edition: <http://www.accessmedicine.com>.)

adjacent bones, muscles and nerves<sup>1</sup>. Most common sites affected are the following, in descending order: femur, pelvis, and tibia, bones of the feet, hands and wrists.<sup>2</sup> Its natural course, if left untreated, would be losing the liquid content slowly, and then eroding to the adjacent soft tissue once it becomes osmotically active.<sup>3</sup> The lesion is apparent when the factor VIII level is <1%.<sup>4</sup>

The etiology of pseudotumor is still unknown. Ghormley, et al.<sup>5</sup> reviewed 6 out of the 44 cases of hemophiliacs with pathological changes in the bones. They have concluded that the tumors have three possible mechanisms: first, it could arise from bleeding in a joint space which later on extends to the bone, producing pressure and erosion; second, it could start as a subperiosteal hemorrhage, leading to ossification then later

to bone destruction; and lastly, it could arise from a cortical or medullary hemorrhage leading to cystic changes that later on damage the bone resulting in fracture and more bleeding. According to Hilgartner,<sup>6</sup> the first type is common in soft tissues of the thigh and buttocks, while the second type is seen in the calcaneus and ileum.

Pseudotumor may contain blood products in different stages of evolution.<sup>7</sup> D'Young<sup>3</sup> reported three distinct zones: hemosiderin in the inner zone, an inelastic fibrous middle zone and an elastic reticular outer zone, the latter of which may cause vascular formation. It can also be classified according to location.<sup>4</sup> The proximal type, commonly seen in the adult population, involves the pelvis and femur; and the distal type which involves the hand and foot, commonly associated with children. The proximal type, seen in this

**Table 3.** Pathological features of pseudotumor differentiating it from other diseases.

PSEUDO-TUMOR	ANEURYSMAL BONE CYST	ROUND CELL TUMOR	SARCOMA
multilocular	multilocular	multilocular	unilocular
cystic	cystic	solid enhancing component (although it can have hemorrhagic foci when it bleeds)	solid enhancing component (although it can have hemorrhagic foci when it bleeds)
well defined border	well defined border	well defined border in most cases	infiltrative
different age of hemorrhages	not prone to recurrent episodes of bleeding	usually one age	usually one age

patient, has a poorer prognosis compared to the distal type.

On physical examination, pseudotumors are characterized by a localized yet enlarging mass. The latter is due to accumulation of blood components that encroach on nearby structures. Muscle necrosis, bone destruction, joint contracture and compartment syndrome eventually ensue. It is usually painless unless it compresses the nerves.<sup>8</sup> Superimposed infection that could lead to a cutaneous fistula or fistula through the bowel is a frequent complication.<sup>9</sup>

In a case report by Shaheen, the bone is destroyed with areas of new bone formation, calcification and ossification of surrounding soft tissues.<sup>4,9</sup> In pseudotumors arising from the bone, radiographs would also show lytic lesions with a well-delineated margin. Calcifications and ossifications may be seen in the internal matrix and is oftentimes accompanied by reactive sclerosis.<sup>7</sup> Lesions arising from the soft-tissue can also manifest as non-specific masses. The subperiosteal hemorrhage may be seen as an uplifting of periosteum.<sup>7</sup> This may not be detected anymore when the entire bone structure is distorted as in the patient's case.

CT scan and MRI are useful in determining the extent of damage. CT scan is helpful in evaluating the bone while MRI is superior in identifying the soft tissue and intramedullary spaces.<sup>7</sup> According to Stafford,<sup>7</sup> the differential diagnosis of pseudotumor is largely academic because a high index of suspicion is warranted if the typical radiographic findings are seen in a patient with a bleeding disorder. Aspirating the content of the mass is contraindicated as this could lead to life-threatening bleeding, fistula formation and infection.<sup>9</sup>

**Perioperative Management**

Treatment protocols for hemophilia patients undergoing surgery are well established. These include the following: 1) surgical procedure is a multi-disciplinary concern and should be well coordinated with a team experienced in handling hemophiliacs; 2) the hospital should have adequate laboratory support for reliable monitoring of clotting factors; 3) pre-operative inhibitor screening should be done; 4) availability of sufficient clotting factor concentrates should be ensured; and lastly, 5) the duration of the surgery should be anticipated to determine the amount of clotting factor concentrate to be prepared. For pseudotumor, its management is also dependent on the size, rate of growth and effect on adjoining structures.<sup>10</sup>

If a major surgery is required, FVIII level should be raised to normal and kept at this level for at least seven days or until the wound has completely healed.<sup>1</sup> Ahlberg recommends that FVIII concentrate should be given to raise the factor level to > 50%.<sup>9</sup> This patient's FVIII level was <1% prior to operation. The dose required to raise FVIII is dependent on the plasma volume and the level to which FVIII is necessitated. For every FVIII unit per kilogram of body weight infused, the plasma level rises approximately 2%. Table 4 summarizes the replacement therapy in major and minor operations, while Table 5 outlines the steps made for computing the required FVIII.

3000 units of FVIII concentrate was needed to achieve the desired level for our patient. A repeat FVIII level assay two hours after the infusion was 186%. Subsequent doses of FVIII concentrate was determined based on its half life of 8-12 hours. Thus, after the loading dose, 1500 units was given every 8 hours for 3 days, and then reduced to every 12 hours.

The patient's hip disarticulation lasted for four hours. One unit of packed red cells was transfused. His vital signs were stable throughout the procedure and there was minimal bleeding post-operatively. The replacement was continued for 11 days until the wound completely healed.

Before the advent of FVIII concentrate, pseudotumors carried a high risk of mortality.<sup>4</sup> The cornerstone of management then was immobilization<sup>3</sup> and transfusion of fresh frozen plasma.<sup>11</sup> Immobilization eventually leads to muscular atrophy resulting in muscular weakness and worsened hematomas.<sup>3</sup> Multiple transfusions, on the other hand, cause volume overload, cerebral edema and in some, heart failure.

According to Chandy,<sup>12</sup> other treatment options include rest, ice, and compression, avoidance of aspirin, rehabilitation, and tranexamic acid. However, this is effective only for very small pseudotumors. Surgery, including amputations, must still be considered for large tumors. Distal pseudotumors in children respond well to immobilization and frequently resolve. However, cast immobilization generally fails to prevent progression of the lesion especially in proximal lesions. As such, recurrence and progression is the rule.<sup>13</sup> In the case series described by Ghormley,<sup>5</sup> four of the six patients died because of delays in the diagnoses and lack of proper transfusion. One case survived due to multiple citrate transfusions and the other case was lost to follow-up.

**Table 4.** Recommended replacement therapy in hemophilia.

Therapeutic Material	MINOR BLEEDING		MAJOR BLEEDING	
	Loading Dose	Maintenance Dose	Loading Dose	Maintenance Dose
cryoprecipitate	not required	1.25-1.75 bags/10 kg q12 x 1-3 days	3.5 bags/10kg	1.75 bags/10kg q8 x 1-2 days then q12 thereafter
purified Factor VIII	not required	10-15 U/kg q12 x 2-4 days	30 U/kg	10-15 U/kg q8 x 1-2 days then q12 thereafter
fresh or frozen citrated plasma	not required	10-15 mL/kg q12 x 2-4 days	30 ml/kg	15 ml/kg q8 x 1-2 days then q12 thereafter

**Table 5.** Computation of FVIII concentrate.<sup>1</sup>

1. Determine the patient's weight in kilograms.
2. Determine the desired factor VIII level needed for the operation.
3. Compute the needed by multiplying the level desired with the weight.

$$\text{Units needed} = (\text{wt kg})(\text{desired FVIII level})(0.5)$$

Pseudotumor has been shown to recur.<sup>14</sup> Physiotherapy in one study proved to be beneficial and effective in managing pseudotumors conservatively.<sup>3</sup> Radiotherapy could also be considered.<sup>13</sup>

Essential to managing patients with hemophilia is counseling. They need psychosocial and psychological support in coping with the illness. Not only should the patients be counseled, but their families as well. Financial support and limitations of activities of daily living often confront families. Hemophiliacs should be encouraged to acknowledge their strengths as well as their restrictions. These should not discourage them from being functional members of the society. They should also be encouraged to continue with their tasks, and should choose activities that have lower risk of injuries. Their families should be aware and must be fully informed of at least the basic information about the medical and economic aspects of hemophilia. If and when the need for medical attention should arise, they should be able to recognize this need and should be able to assist immediately in whatever way possible. It is worth knowing that there are advocacy groups assisting hemophiliacs.

#### Acknowledgments

Reverend Donald Kill, facilitated the procurement of FVIII for Project Share. Columban Fathers. Missionary Society of St. Columban. P.O. Box 1066 7200 Ozamis City. [revdonaldkill@yahoo.com](mailto:revdonaldkill@yahoo.com).

Project Share. A humanitarian program devoted solely to donating factor concentrates to the communities in developing countries. LA Kelly Communications, Inc, 68 East Main street, suite 102, Georgetown, Massachusetts 01833 USA. [www.kelleycom.com](http://www.kelleycom.com).

Hemophilia Association of the Philippines for Love and Services, Inc (HAPLOS). Villa Maria de Asturias Building 1240 Asturias Street, Sampaloc, Manila

#### References

1. Roberts HR, et al. Hemophilia A and hemophilia B. In: Lichtman MA, et al, eds. Williams Hematology, 7<sup>th</sup> ed. New York: The McGraw-Hill Companies, Inc; 2006. pp. 1867-1883.
2. Gilbert MS. Characterizing the hemophilic pseudotumor. *Ann N Y Acad Sci.* 1975; 240:311-5.
3. D'Young AI. Conservative physiotherapeutic management of chronic haematomata and haemophilic pseudotumours: case study and comparison to historical management. *Haemophilia.* 2009;15(1):253-60.
4. Shaheen S, Alasha E. Hemophilic pseudotumor of the distal parts of the radius and ulna: a case report. *J Bone Joint Surg Am.* 2005;87(11):2546-9.
5. Ghormley RK, Clegg RS. Bone and joint changes in Hemophilia: With report of cases of so-called Hemophilic Pseudotumor. *J Bone Joint Surg Am.* 1948;30A(3):589-600.
6. Hilgartner MW, Arnold WD. Hemophilic pseudotumor treated with replacement therapy and radiation: report of a case. *J Bone Joint Surg Am.* 1975;57(8): 1145-6.
7. Stafford JM, James TT, Allen AM, Dixon LR. Hemophilic Pseudotumor: Radiologic-Pathologic correlation. *Radiographics.* 2003; 23(4):852-6.
8. Magallon M, Monteagudo J, Altisent C, et al. Hemophilic pseudotumor: multicenter experience over a 25-year period. *Am J Hematol.* 1994;45(2):103-8.
9. Ahlberg, AK. On the natural history of hemophilic pseudotumor. *J Bone Joint Surg Am.* 1975;57(8):1133-6.
10. World Federation of Hemophilia. Guidelines for the Management of Hemophilia. Canada:World Federation of Hemophilia;2005.
11. Staas WE Jr, Ditunno JF Jr, Gartland JJ, Shapiro SS. Lower extremity amputation in Hemophilia: case report and review of surgical principles. *J Bone Joint Surg Am.* 1972; 54(7):1514-22.
12. Chandy M. Treatment options in the management of hemophilia in developing countries. Canada:World Federation of Hemophilia. 2005;37.
13. Espandar R, Heidari P, Rodriguez-Merchan EC. Management of haemophilic pseudotumors with special emphasis on radiotherapy and radio embolization. *Haemophilia.* 2009;15(2):448-57.
14. Valentino LA, Martinowitz U, Doolas A, Murali P. Surgical excision of a giant pelvic pseudotumour in a patient with haemophilia A. *Haemophilia.* 2006;12(5):541-4.