

Osteosarcoma in the Preadolescent Filipino Patient

Edward H.M. Wang,¹ Julius N. Valenzuela,¹ Ana Cristina D. Decenteceo,¹ Amy Goleta-Dy,² Ana Patricia A. Alcasabas,² Ariel M. Vergel de Dios,³ Ma. Victoria T. Serrano,¹ Cesar L. Dimayuga¹ and Albert Jerome C. Quintos¹

¹Section of Orthopaedic Oncology, Department of Orthopedics, College of Medicine and Philippine General Hospital, University of the Philippines Manila

²Section of Pediatric Oncology, Department of Pediatrics, College of Medicine and Philippine General Hospital, University of the Philippines Manila

³Department of Pathology, College of Medicine, University of the Philippines Manila

ABSTRACT

Objective. Classic high-grade osteosarcoma is uncommon in preadolescents (≤ 10 years of age). The possibilities of clinicopathologic differences from the typical adolescent osteosarcoma patient have been raised. We sought to compare the presentation, treatment and survival of this subgroup of patients with published rates in order to determine if there is a need to use a treatment regimen different from that for regular adolescent osteosarcoma patients.

Methods. Records of the University of the Philippines–Musculoskeletal Tumor Unit (UP-MuST) over a 15-year period (1993–2008) were reviewed and data collected on patients 10 years and younger with biopsy-proven classic high-grade intramedullary osteosarcoma who underwent complete treatment by the Unit. Demographics and survival rates were then compared with published rates for preadolescent and regular adolescent osteosarcoma cases.

Results. There were fourteen patients; (6M:8F; age: 4–10 years). The most common presentation was a painful mass in the distal femur (8); the tumors most commonly had osteoblastic histology (12). Treatment consisted of neoadjuvant chemotherapy, wide surgical excision through ablation (9) or limb-saving surgery (5), and postoperative chemotherapy. There was a good histologic response (over 90% tumor necrosis) in four patients. Seven patients are ANED (alive no evidence of disease) 25 to 186 months after diagnosis. Five-year survival estimate is 52%, compared to a dismal 5 to 10% 15 years ago.

Conclusion. Clinicopathologic presentation, clinical course, and overall survival in this subgroup of patients are comparable with

published results for both preadolescent and adolescent osteosarcoma patients. There is no need to alter the present treatment regimen for this group of young patients.

Key Words: osteosarcoma, preadolescent, presentation, treatment, survival

Introduction

Classic high-grade intramedullary osteosarcoma usually occurs in patients in their second decade of life. Data from the University of the Philippines–Musculoskeletal Tumor Unit (UP-MuST) over a 15-year period (1993–2008) show a peak incidence during the teenage years.¹ Children 10 years old and younger (preadolescents) are not as frequently affected but form a distinct subset of patients not only because of postoperative concerns of limb length discrepancies but more importantly because of the possibility of differences from the regular adolescent patient in terms of clinical presentation and prognosis. Age has been implicated as a prognosticator in cancers such as acute lymphocytic leukemia, neuroblastoma, and medulloblastoma; the question whether this is true or not for osteosarcoma has been raised by some authors.²

Several early studies^{3,4,5} suggest a different prognosis in this group of young patients. Treatments, however, in these studies, were often inhomogeneous—not all patients received the standard combination of chemotherapy and surgery. On the other hand, more recent literature^{2,6,7,8,9} report no difference in survival between the preadolescent and adolescent patient with osteosarcoma, these latter authors concluding that there is thus no need for an alteration of standard chemotherapeutic protocol.

Our study is a case series of preadolescent osteosarcoma patients who received complete treatment from the UP-Musculoskeletal Tumor Unit at the Philippine General Hospital. Their presentation, pathologic features, treatment, and survival rates will be described and compared with published reports on osteosarcoma in both the preadolescent and adolescent patient.

Methods

The database of the UP-Musculoskeletal Tumor Unit (UP-MuST Unit) contains all patients seen by the Unit from its establishment in 1993 to the present. All patients with a

Presented as free paper at the 60th Philippine Orthopedic Association Convention, November 9-14, 2009, EDSA Shangri-la Hotel, Mandaluyong City, Philippines.

Corresponding author: Edward H.M. Wang, MD, MSc
Department of Orthopaedics
Philippine General Hospital
University of the Philippines Manila
Taft Avenue, Ermita, Manila 1000 Philippines
Telephone: +632 5548466
Fax No: +632 5218538
Email: ehmwang@skybroadband.com.ph

histologic diagnosis of classic high-grade intramedullary osteosarcoma 10 years old and younger in the database between Jan 1993 and June 2008 (to allow follow-up of at least two years) were identified. We included only those patients who received treatment according to the standard osteosarcoma protocol of the Unit: two to three courses of neoadjuvant chemotherapy with doxorubicin (adriamycin) and cisplatin (CDDP) followed by surgery. Surgery was tumor excision with wide margins either through limb salvage or amputation. This was followed by further chemotherapy—from 1993 to 2006, the number of courses and kinds of chemotherapeutic drugs were modified if postoperative histopathologic report of tumor necrosis was classified as poor according to the classification of Huvos (less than 90%).¹⁰ Beginning 2007, neoadjuvant chemotherapeutic drugs were continued whatever the necrosis rate, since a local study¹¹ showed no survival advantage to changing chemotherapy.

We excluded those patients who did not receive complete treatment (e.g., those who received inadequate or no chemotherapy), those who refused surgery, and those who were partially treated in other hospitals. Also excluded were patients who did not have reported tumor necrosis (e.g., patients who underwent surgery prior to chemotherapy) as tumor necrosis was deemed an important variable for comparison with other series, especially in relation to treatment and prognosis.

In order not to miss out on cases, a review was also undertaken of other records available at the Philippine General Hospital, including the admissions and discharge logbooks of the Departments of Orthopedics and Pediatrics, case records of the Out Patient Department and the Cancer Institute, and the files of the Departments of Pathology and Laboratory for records of biopsy, gross pathology, and histologic tumor necrosis results.

The following data were collected from each of the identified patients: age, sex, location or primary site, histopathologic diagnosis, Enneking tumor stage, date and type of biopsy, neoadjuvant chemotherapy, type of surgery, tumor necrosis, adjuvant chemotherapy, complications, metastasis, and present status. All patients were followed up for at least 24 months from time of histologic diagnosis, or until death.

Similar to many other studies^{2,7,8,9,12} we chose 10 years of age as the cut-off age. Lee⁸ states that since the specific age for puberty could not be defined, 10 years of age was chosen to purely select those patients who were in their preadolescent period. It was hoped that this arbitrary selection would offset the lack of endocrinologic data which was also true in our situation.

Results

A total of 14 patients fulfilled the criteria for inclusion into the series (Table 1). There were six boys and eight girls,

with an age range of four to 10 years. The primary site was the distal femur in eight, proximal tibia in three, proximal humerus in two, and the proximal fibula in one. In almost all patients, clinical presentation was a growing mass accompanied by pain (Figure 1). One patient presented (AU) with a pathologic fracture of the proximal humerus while two patients developed pathologic fractures of the distal femur (RA, MS) while undergoing neoadjuvant chemotherapy (Figure 2). The treatment protocol was not altered in these patients and all three pathologic fractures went on to complete healing prior to surgery.

Patients underwent an initial biopsy either via core needle (4) or open method (10). A histopathologic diagnosis of classic high-grade intramedullary osteosarcoma was confirmed by the Unit pathologist, with the osteoblastic subtype in the majority of cases (12) and the chondroblastic in two.

After the initial radiographs of the tumor, staging studies were undertaken, including CT or MR imaging of the lesion (local staging), a chest CT scan, and a total body bone scan (systemic staging). Among the blood examinations, LDH and alkaline phosphatase were routinely included. Other studies such as 2-D echocardiography, renal function test, and audiometry were undertaken as baseline examinations prior to chemotherapy. Neoadjuvant chemotherapy was usually given for three courses, using doxorubicin (adriamycin) and cisplatin. Tumor excision was scheduled three to four weeks from the end of neoadjuvant chemotherapy.

A repeat MR imaging of the affected extremity was taken prior to surgery and a wide surgical margin planned for tumor excision. Wide margins (Figure 3) were defined as follows: 5 cm from the intramedullary extent of the lesion and 2–3 cm from the soft tissue extent, as defined by MR images. Surgery could be either ablative surgery (9) or limb saving surgery (5); but it was necessary that wide margins be achieved in all cases.

Six patients underwent hip disarticulation for distal femoral osteosarcoma, two underwent above knee amputation for a fibular and a tibial lesion, and one had a forequarter amputation for a large proximal humerus lesion.

In limb saving surgery, the tumor is also excised with wide margins but unlike amputations, the arm or leg is preserved. The location of the osteosarcoma in the five patients who underwent limb saving surgery were the distal femur (2), proximal tibia (2), and proximal humerus (1). The resulting bone defects were reconstructed with a tumor prosthesis (1), Ilizarov bone induction and lengthening (1), and vascularized fibular graft (1). At the time of writing, the patient who had reconstruction with a tumor prosthesis had undergone three further surgeries to lengthen the involved leg, each time adding extra length to the prosthetic metal segment. The second and third patients continue to have their limbs lengthened using the Ilizarov technique with

Table 1. List of patients with corresponding variables

Patient	Age/Sex	Site	Histology Type	Pathologic Fracture	Pre-op Chemo	Surgery	Tumor necrosis	Post-op chemo	Remarks
VA	4/M	Humerus/P, R	Osteoblastic	(-)	Yes	AMP	40%	Yes	DOD @ 17 mos
MMM	4/F	Femur/D3,L	Osteoblastic	(-)	Yes	AMP	70%	yes	DOD @ 10 mos.
MJP	5/F	Femur/D3,L	Osteoblastic	(-)	Yes	AMP	50%	yes	DOD @ 8 mos.
EV	7/F	Femur/D3, L	Osteoblastic	(-)	Yes	AMP	60%	yes	ANED @ 121 mos.
MJM	8/M	Femur/D3, R	Osteoblastic	(-)	Yes	LSS	50%	yes	ANED @ 127 mos.
ANU	8/F	Humerus/P, R	Osteoblastic	(+)	Yes	LSS	50%	yes	ANED @ 63 mos.
AFG	8/F	Femur/D3, L	Osteoblastic	(-)	Yes	AMP	50%	yes	DOD @ 10 mos.
MS	9/F	Femur/D3,L	Osteoblastic	(+)	Yes	LSS	90%	yes	ANED @ 76 mos.
RA	10/M	Femur/D3,R	Osteoblastic	(+)	Yes	AMP	96%	yes	ANED @ 186 mos.
JD	10/M	Tibia/P3, R	Osteoblastic	(-)	Yes	LSS	95%	yes	ANED @ 25 mos
CD	10/M	Fibula/P3, R	Osteoblastic	(-)	Yes	AMP	90%	yes	ANED @ 146 mos.
MLC	10/M	Tibia/P, L	Chondroblastic	(-)	Yes	AMP	15%	yes	DOD @ 33 mos
ZA	10/F	Femur/D3, R	Osteoblastic	(-)	Yes	AMP	60%	yes	DOD @ 5 mos
ATH	10/M	Tibia/P, R	Chondroblastic	(-)	Yes	LSS	30%	yes	DOD @ 14 mos

* P- proximal; D3 – Distal 3rd; P3 – Proximal 3rd; AMP – amputation;
LSS- limb-saving surgery; ANED – Alive, no evidence of disease;
DOD – Dead of disease

external ring fixators. Reconstruction for the fourth patient utilized a vascularized fibula from the leg which included the proximal epiphysis or growth plate with the objective that the entire transplanted fibula would continue to grow in length and diameter to approximate the contralateral humerus. The fifth patient died of disease after undergoing a resection arthrodesis (knee fusion).

Reconstruction for limb saving surgeries can be immediate or staged. Immediate reconstruction in our patients utilized the Ilizarov bone lengthening technique or vascularized fibular grafting. In staged surgeries, the bony defect is temporarily reconstructed with a spacer made of antibiotic-impregnated bone cement wrapped around an intramedullary nail (usually a Kuntscher nail). Once the family has recovered financially from the expenses of treatment and the patient has recovered medically from chemotherapy (usually six to 12 months), a second surgery is performed to replace the nail–cement construct, usually with a tumor prosthesis (Figure 4).

Tumor necrosis ranged from 15 to 96% with four patients achieving very good results (above 90%). In seven patients, tumor necrosis was in the range of 50 to 70%, while three patients had tumor necrosis of 15, 30, and 40%, respectively. Postoperative chemotherapy is dependent on

tumor necrosis—those with good response (90% or higher) are continued on three more courses of their preoperative regimen, i.e. doxorubicin and cisplatin. Those with less than 90% tumor necrosis (poor histologic responders) are shifted to a regimen of either ifosfamide and etoposide (IE) or ifosfamide, carboplatin, and etoposide (ICE). Since 2007, we have not recommended this change for patients with poor histologic response, based on the fact that there has been no evidence both in the literature and in our own evaluation for any significant improvement in survival with a change in chemotherapeutic regimen, not to mention the prohibitive financial cost of such a shift, a burden our patients can ill afford.¹¹

Of the 14 patients, seven are alive with no evidence of disease (ANED) while seven are dead of disease (DOD). Those alive with no evidence of disease have a survival period ranging from 25 to 186 months, with all patients followed up for at least 24 months. (Survival is measured from date of histologic diagnosis.) All four patients with good tumor necrosis ($\geq 90\%$) are alive with no evidence of disease; the three other live patients have tumor necroses of 50% (2) and 60% (1). On the other hand; except for one patient (MLC) who died at 33 months, all patients dead of disease died within 24 months from diagnosis. Tumor

necrosis for this group ranged from 15 to 70%, with most patients below 50%. The actuarial five-year survival estimate was 52% (95% CI) (Figure 5). All seven patients who remain alive have returned to or have graduated from school.

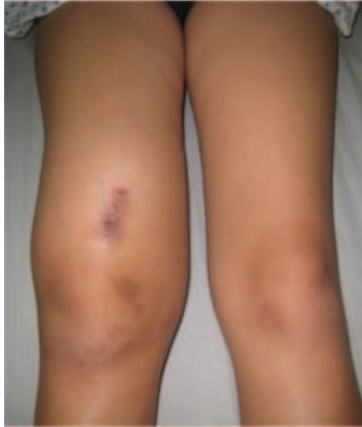

Figure 1. A painful mass around the knee is the most common presentation of osteosarcoma

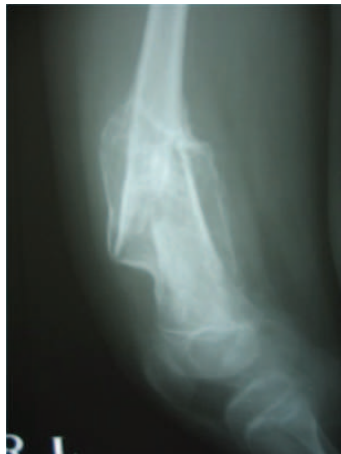

Figure 2. Pathologic fracture of the distant femur

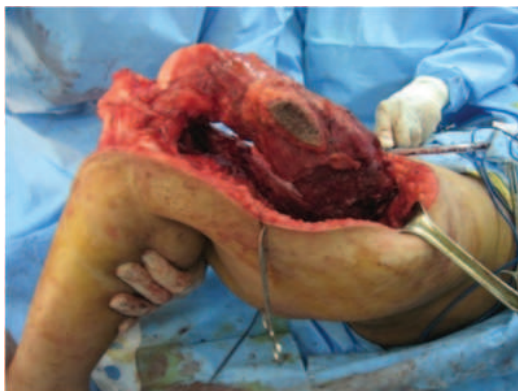

Figure 3. Wide excision of distal femur osteosarcoma

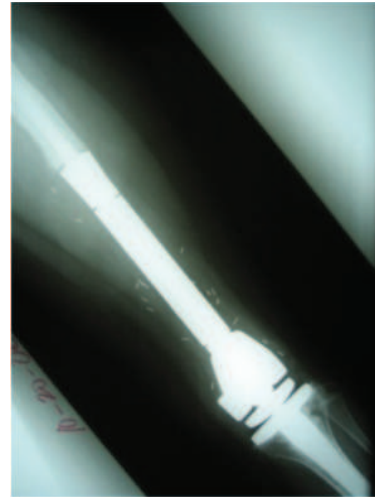


Figure 4. Reconstruction of the knee joint using a tumor prosthesis after wide excision of a distal femur osteosarcoma.

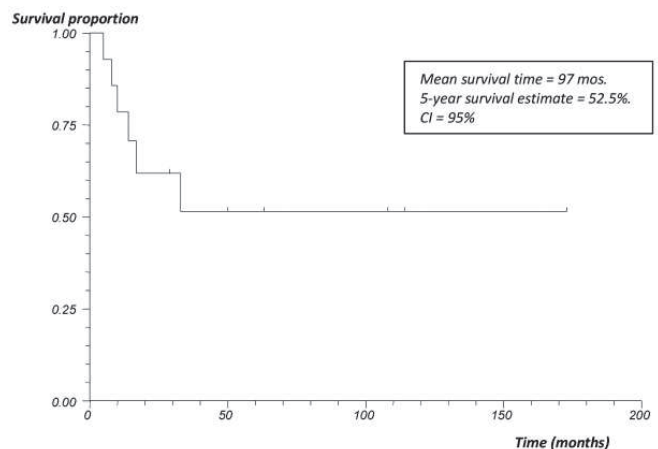


Figure 5. Kaplan-Meier survival curve for overall survival (Source: Wang EHM, Fernando G, Goleta-Dy A , et. al. Osteosarcoma in a developing country, small successes against gargantuan odds. 2010. Unpublished)

Discussion

Osteosarcoma in the preadolescent patient is uncommon. Patients in the first decade of life account for 10% of the total osteosarcoma population seen at the University of the Philippines–Musculoskeletal Tumor (UP-MuST) Unit,¹ slightly lower than that reported by Bacci⁶ (14.5%) and Hsieh⁷ (17%).

The question has been raised whether the preadolescent patient is different from the usual adolescent patient with classic high-grade intramedullary osteosarcoma in terms of clinical presentation and prognosis. Reports from literature are not uniform. McKenna³ observed that younger patients developed lung metastases earlier than their older counterparts while Scranton⁴ and Winkler⁵ noted a poorer prognosis among preadolescents. On the other hand, the

more recent literature^{6,7,8,9,12,14} reports comparable event-free and overall survival rates among the preadolescent and adolescent osteosarcoma populations.

Our paper is a retrospectively collected series of preadolescent Filipino patients (less than 10 years of age) from the UP-MuST Unit over a period of 15 years. We included only those who received complete treatment and who had both preoperative and postoperative chemotherapy. At the Philippine General Hospital, government subsidy is unable to cover for patients' full course of treatment and close to half of osteosarcoma patients are unable to complete the entire course of chemotherapy. At the same time, it was necessary to exclude those who had surgery prior to chemotherapy (e.g., amputations for large lesions followed by postoperative chemotherapy) because it would not have been possible to measure histologic response to chemotherapy (tumor necrosis), a variable we deemed important in comparing our patients with those in literature.

Patients in our series seem to be no different from those of similar series. A painful mass around the knee joint is the most common presenting symptom of osteosarcoma.^{1,15} In eleven of our 14 patients, the knee joint was involved (distal femur or proximal tibia). In all studies of preadolescent patients with osteosarcoma, lesions were most commonly found around the knee joint especially the distal femur with no statistically significant difference in terms of location between preadolescent and adolescent patients.^{6,7,8,9,12} These studies also concluded that tumor site was not a significant prognosticator for outcome in either age group.

Another presenting complaint is a pathologic fracture of which we had one patient in our series (7%); two other pathologic fractures occurred during treatment. This is similar to the 8% reported by Bacci,⁶ but slightly lower than the 15% (two out of 13) incidence on presentation reported by Hsieh⁷. Kosakewich¹³ and Rytting⁹ found the overall incidence of pathologic fractures similar in both preadolescent and adolescent patients with osteosarcoma. They added further that the presence of a pathologic fracture was not a risk factor for poor prognosis in either group, in stark contrast to common belief and practice which proposes amputation once a patient sustains a pathologic fracture because of the fear of local tumor spread. Our results would seem to concur with this finding; all three of our patients who sustained pathologic fractures through their osteosarcoma are ANED (alive with no evidence of disease) at latest follow-up (63, 76, 186 months). Two underwent limb saving surgery while one had a hip disarticulation. Furthermore, two of these three patients had good chemotherapy-induced histologic response (tumor necrosis \geq 90%).

Tumor necrosis is considered one of the most important prognostic variables for survival in classic osteosarcoma.¹⁴ Four (29%) of our patients had tumor necrosis equal to or

more than 90%, tumor necrosis for the other patients ranging from 15 to 70%. Hsieh⁷ reported 20% incidence of good tumor necrosis, Lee⁸ noted 32%, while Bacci¹² reported 66%. Cho², Bacci⁶, and Lee⁸ reported that tumor necrosis had a significant prognostic impact and found this to be true in both adolescent and preadolescent patients. In contrast, Hsieh⁷ found tumor necrosis to be significantly different in the two groups but that it carried no significant prognostic value. A similar finding was noted by Rytting even while good tumor necrosis showed a trend for better survival.⁹ In our series, all four patients with good histologic response to chemotherapy (tumor necrosis) were ANED. None of the other living patients had tumor necrosis less than 50%. In the group of patients who were dead of disease (DOD), tumor necrosis was 50% or less in five of seven cases (range 15–70%).

It is interesting to note that in our patients seven years of age and younger, three out of four (75%) are dead compared to four out of 10 (40%) in the older preadolescents. Tumor necrosis in these young preadolescents was relatively lower, none of whom could be categorized as having achieved good histologic response (40-50-60-70%). All four patients had undergone amputation. Lee et al.⁸ also noted a low 14% incidence of good responders in the less than seven year old population, with an amputation rate of 43% (compared to 91% for the entire preadolescent group). Surprisingly, however, there was no difference in their five-year event-free survival (EFS) compared with the older preadolescents.

Aside from presentation and prognostication, another major concern in preadolescent osteosarcoma patients is postoperative limb length discrepancies especially for those patients who have undergone limb salvage surgery. It is for this reason that a relatively higher rate of amputation is reported in many series of preadolescent osteosarcoma patients.^{2,6,8,12} Only five of 14 patients (36%) in our series underwent limb saving surgery; this type of surgery being usually reserved for older patients in the ages ranging from eight to 10 years. Hsieh⁷, on the other hand, reported a limb salvage rate of 77% (10/13), Lee⁸ reported 91% (29/32), while Bacci¹² reported 63%. We attribute our lower rate of limb salvage to two possible factors. One is the initial tumor size on presentation. Despite a decrease in size of the tumor after neoadjuvant chemotherapy, proximity of the tumor to neurovascular structures weighs heavily against the surgeon's decision to propose limb saving surgery. A second factor may be the parents' willingness and capability to undergo further surgical procedures after definitive tumor excision. In a growing child, the initial limb saving surgery to remove the osteosarcoma usually requires subsequent operative procedures to lengthen the limb until full growth is achieved and this entails additional recurring costs which many of our patients may not be capable of financing. Amputation then becomes a more cost-effective alternative,

especially because of the easy availability of affordable yet durable artificial limb prostheses.

Our overall five-year survival estimate is 52%. This compares well with that reported by Hsieh⁷ (51.3%), Lee⁸ (73.1%), Cho² (53.7%), and Bacci⁶ (71%). The case controlled studies of Hsieh⁷ and Lee⁸ found no difference in survival (whether EFS or OS) between the preadolescent and the adolescent osteosarcoma patient. Bacci^{6,12} and Rytting⁹ compared their results with those of older patients from their institutions treated with the same protocol and those in published reports and also found no differences in survival estimates, acknowledging the possibility that advances in chemotherapy and surgery may have been instrumental in improving the prognosis of the young osteosarcoma patient.

In conclusion, it would seem that osteosarcoma presenting in the preadolescent Filipino patient is no different from the usual osteosarcoma in the adolescent patient in terms of clinical presentation, histologic characteristics, and prognosis. We concur with the suggestions of other authors that the current strategy of using the same treatment protocol in this group of young patients is warranted.

References

1. Wang EHM, Vergel de Dios AM. Bone Tumors in Filipinos. Makati City, Philippines: The Bookmark Inc.; 2007. pp. 100-115.
2. Cho WH, Lee SY, Song WS, Park JH. Osteosarcoma in preadolescent patients. *J Int Med Res.* 2006;34(6):676-81.
3. McKenna RJ, Schwinn CP, Soong KY, et al. Sarcomata of the osteogenic series (Osteosarcoma, Fibrosarcoma, Chondrosarcoma, Parosteal Osteogenic Sarcoma, and Sarcomata Arising in Abnormal Bone): an analysis of 552 cases. *J Bone Joint Surg (Am).* 1966;48:1-26.
4. Scranton PE Jr, De Cicco FA, Totten RS, et al. Prognostic factors in osteosarcoma. A Review of 20 Years' Experience at the University of Pittsburgh Health Center Hospitals. *Cancer.* 1975;36(6):2179-91.
5. Winkler K, Beron G, Kotz R, et al. Neoadjuvant chemotherapy for osteosarcoma: results of a cooperative German/Austrian study. *J Clin Oncol.* 1984;2(6):617-24.
6. Bacci G, Balladelli A, Palmerini E, et al. Neoadjuvant chemotherapy for osteosarcoma of the extremities in preadolescent patients: the Rizzoli Institute Experience. *J Pediatr Hematol Oncol.* 2008;30(12):908-12.
7. Hsieh MY, Hung GY, Yen HJ, et al. Osteosarcoma in preadolescent patients: experience in a single institute in Taiwan. *J Clin Med Assoc.* 2009;72(9):455-61.
8. Lee JA, Kim DH, Lim JS, et al. The survival of osteosarcoma patients 10 Years old or younger is not worse than the survival of older patients: a retrospective analysis. *Cancer Res Treat.* 2007;39(4):160-4.
9. Rytting M, Pearson P, Raymund AK, et al. Osteosarcoma in preadolescent patients. *Clin Orthop Relat Res.* 2000;373:39-50.
10. Meyers PA, Heller G, Healey J, et al. Chemotherapy for nonmetastatic osteogenic sarcoma: The Memorial Sloan-Kettering Experience. *J Clin Oncol.* 1992; 10(1):5-15.
11. Orillaza NS, Wang EHM, Goleta-Dy A, et al. Effectiveness of Replacement Salvage Chemotherapy for Osteosarcoma with Poor Histologic Response. (Presented at 7th Asia-Pacific Musculoskeletal Tumor Meeting, Beijing, China). Unpublished.
12. Bacci G, Longhi A, Bertoni F, et al. Primary high-grade osteosarcoma: comparison between preadolescent and older patients. *J Pediatr Hematol Oncol.* 2005;27(3):129-34.
13. Kozakewich H, Perez-Atayde AR, Goorin AM, et al. Osteosarcoma in Young Children. *Cancer.* 1991;67(3):638-42.
14. Weis L. Common Malignant Bone Tumors: Osteosarcoma. In: Simon MA, Springfield D, eds. *Surgery for Bone and Soft Tissue Tumors.* Philadelphia: Lippincott-Raven; 1998. pp. 265-274.
15. Hartford CM, Wodowski KS, Rao BN, et al. Osteosarcoma among children aged 5 years or younger: the St. Jude Children's Research Hospital experience. *J Pediatr Hematol Oncol.* 2006;28(1):43-7.