

# Menkes Disease Mimicking Non-Accidental Injury in a Filipino Child

April Grace Dion-Berboso,<sup>1,2</sup> Bernadette J. Madrid,<sup>1,3</sup> Cerissa T. Melendres<sup>2</sup> and Mary Anne D. Chiong<sup>1,2</sup>

<sup>1</sup> Department of Pediatrics, College of Medicine and Philippine General Hospital, University of the Philippines Manila

<sup>2</sup> Institute of Human Genetics, National Institutes of Health, University of the Philippines Manila

<sup>3</sup> Child Protection Unit, University of the Philippines- Philippine General Hospital

## ABSTRACT

We report an 11-month-old male who presented with recurrent seizures, subdural bleed, skull fracture, lightly pigmented hair, and fair lax skin. Copper and ceruloplasmin levels were low and gross deletion of *ATP7A* gene was found confirming the diagnosis of Menkes disease. The presence of subdural bleed and skull fracture prompted a referral to the Child Protection Unit to rule out child abuse.

*Key Words:* Copper, ceruloplasmin, Menkes disease, seizures, abnormal hair, subdural hemorrhage

## Introduction

Menkes disease is an X-linked lethal multisystemic disorder of copper metabolism due to a mutation of the *ATP7A* gene. It has no race predilection and its estimated prevalence is 1 in 100,000 to 1 in 250,000.<sup>1</sup> *ATP7A* is involved in the delivery of copper to the secreted copper enzymes and in the export of excess copper from cells. Copper, together with the copper enzymes are involved in cellular respiration, neurotransmitter biosynthesis, maturation of peptide hormones, free-radical scavenging, cross-linking of elastin, collagen and keratin, and iron homeostasis.<sup>2</sup> In individuals with Menkes disease, there is malfunction of these copper enzymes resulting in multisystemic disturbances characterized as progressive neuro-degeneration and connective tissue dysfunction.<sup>1</sup>

In this paper, we describe an 11-month-old male with Menkes disease who presented with the classic findings of peculiar hair and recurrent seizures, and additional significant findings of subdural bleed and skull fracture which are usually seen in child abuse.

## Clinical Report

P. J. I. is an 11-month-old male who is the youngest in a sibship of 6 born to a non-consanguineous couple of Filipino descent. He was born to a 42-year-old father and 38-year-old

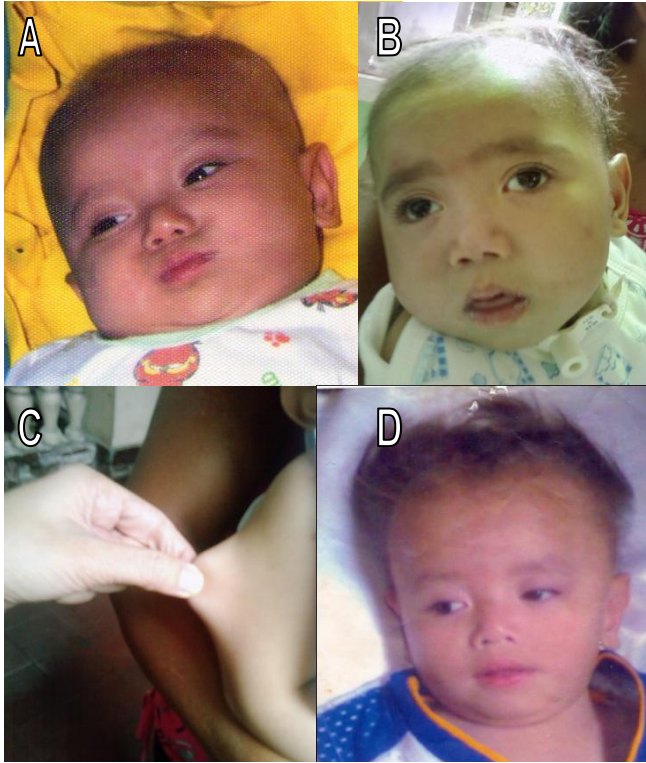G6P5 (5004) mother via spontaneous vaginal delivery. At birth, he had good suck, fair cry and fair activity. At 1 month of age, he was noted to have lightly pigmented hair. At 2 ½ months of age, he started to have seizures characterized as continuous blinking of the eyes, jerking of the upper extremities and drooling. He was brought to a tertiary hospital where he was diagnosed with myoclonic epilepsy probably cryptogenic and cerebral palsy spastic quadriplegic type. He was maintained on Phenobarbital. Laboratory examinations (EEG, cranial MRI, and urine metabolic screen) were ordered but were not done due to financial constraints. Since then, the patient was noted to have poor weight gain, recurrent seizures and multiple episodes of cough and pneumonia requiring frequent hospital admissions.

Physical examination showed that he was proportionately small for age with weight and length below the 5<sup>th</sup> percentile and head circumference below the 2<sup>nd</sup> percentile. He had biparietal prominence, sparse and lightly pigmented hair, pudgy cheeks, and fair lax skin. (Figure 1A, B and C). He had crackles on both lung fields, subcostal retractions, spasticity and hyperreflexia on all extremities. Examination of the heart, abdomen and genitalia were essentially normal.

Cranial CT scan done showed subdural bleed on the left frontal, fronto-parietal and posterior parietal convexities (Figure 2A). Skeletal survey revealed a depressed fracture at the parieto-occipital region (Figure 2B), generalized osteopenia, and metaphyseal flaring of the femurs (Figure 2C). The findings of subdural bleed and depressed skull fracture led to the consideration of a possible non-accidental head injury prompting subsequent referral to child protection specialists. Ophthalmologic evaluation showed normal fundoscopic examination. As part of the metabolic investigation, serum ammonia and phenylalanine level determination were done and revealed normal results. Urine metabolic screen showed increased alanine. Chest radiography showed pneumonia and hyperaerated lungs.

The presence of intractable seizures associated with hair changes and subdural bleed made the suspicion of Menkes disease highly plausible. Serum copper and ceruloplasmin levels were requested and both showed low levels at 0.13 ug/ml (N.V. 0.7- 1.4 ug/ mL) and 7.42 mg/ dL (N.V. 22- 58 mg/ dL), respectively. Gene testing done showed a large deletion of the Menkes gene (*ATP7A*), from exon 5 through

Corresponding author: Mary Anne D. Chiong, MD  
Institute of Human Genetics  
National Institutes of Health  
University of the Philippines Manila  
625 Pedro Gil Street, Ermita, Manila 1000 Philippines  
Telephone: +632 5261725  
Email: maryannechiong@gmail.com



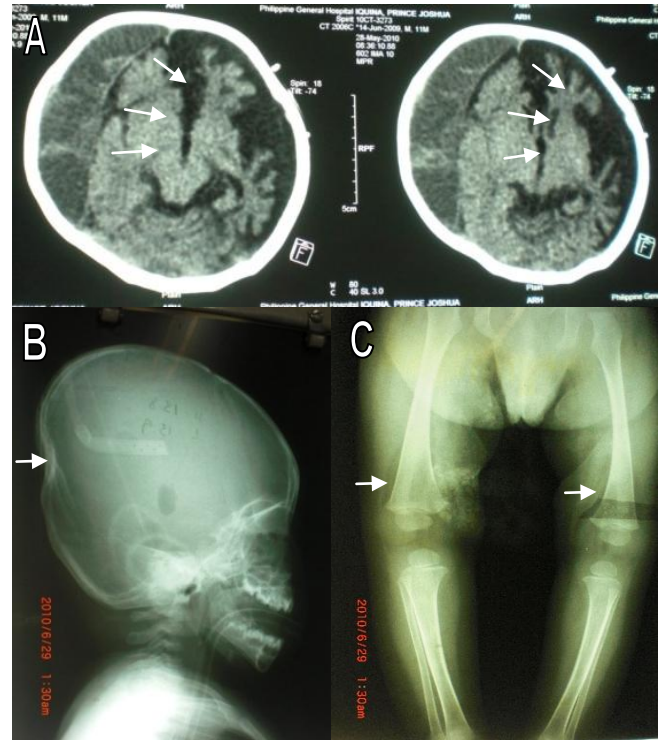
**Figure 1.** (A, B and C) The patient had biparietal prominence, sparse, lightly pigmented hair, pudgy cheeks and fair and lax skin. (D) The patient's older brother with fair skin color and a similar lightly pigmented hair (with permission).

23 confirming the diagnosis. Further tests which included ultrasonography of the kidneys and urinary bladder revealed normal results.

Review of family history (Figure 3) revealed that he had a brother who also had recurrent seizures, a similar lightly pigmented hair, and fair skin (Figure 1D). Investigations done on the brother included a cranial CT scan and an EEG. A diagnosis of cerebral palsy was given. He died at 1 year and 7 months of age due to septic shock. One of the proband's sisters was diagnosed to have ventricular septal defect. No other history of chromosomal aberration or malformation was reported.

### Discussion

The first sign of Menkes disease may be an unusual sparse, lusterless, stubby, depigmented appearance of scalp hair at 1 to 2 months of age. At this time, affected patients may have frontal or occipital bossing, micrognathia, pudgy cheeks and an expressionless appearance. However, these findings are often too subtle to attract attention. Initial psychomotor development is usually unremarkable with normal babbling and smiling up to about 2 to 4 months of age. The baby then ceases to develop and suffers from

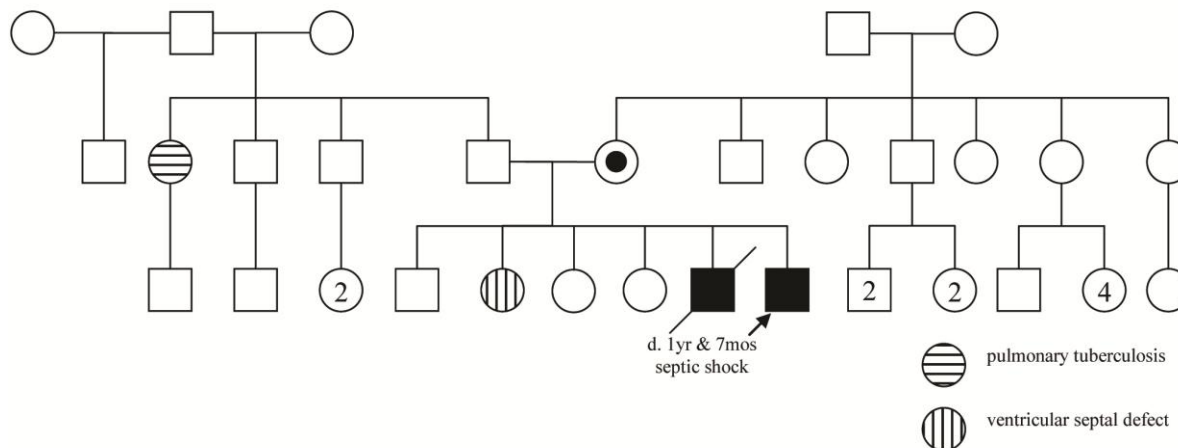


**Figure 2.** (A) Cranial CT scan done showed subdural bleed on the left frontal, frontoparietal and posterior parietal convexities (white arrows). (B and C) Skeletal survey revealed a depressed fracture at the parieto-occipital region (white arrow), generalized osteopenia, and metaphyseal flaring of the femurs (white arrows).

therapy-resistant seizures, motor dysfunction and drowsiness which progresses to lethargy. The patients are typically diagnosed at 3 to 6 months of age, often due to the abnormal hair that is a striking feature of the disease.<sup>2</sup> Our patient presented with seizures at 2 ½ months of age; however, the associated findings in the hair and skin were not initially recognized as part of a syndromic disorder. The findings of subdural bleed and a depressed skull fracture prompted a referral to the Child Protection Unit to rule out child abuse.

The following were considered typical features of Menkes disease, i.e. generalized osteopenia and metaphyseal flaring of the femurs, low copper and ceruloplasmin levels and absence of retinal hemorrhage. Congenital skull fracture has also been reported as a rare presentation of Menkes disease and it was concluded that the disease should be considered in any child who presents with congenital skull fracture.<sup>4</sup>

Menkes disease is a progressive disorder leading to death in early childhood, although some patients survived beyond 5 years of age. Treatment in majority of cases is mainly symptomatic. However, careful medical care and copper administration, may extend life span up to 13 years



**Figure 3.** Pedigree. The proband is the youngest in a sibship of 6 of a non-consanguineous couple of Filipino descent. He had a brother who also had recurrent seizures and lightly pigmented hair and fair skin.

or even more.<sup>2</sup> Infants with Menkes disease who received copper treatment within the neonatal period had better survival than infants who received treatment later.<sup>5</sup> A study done by Kaler et al. showed that early diagnosis and treatment ( $\leq 6$  weeks of age) with copper injections improved brain electrical activity and decreased seizure occurrence in classical Menkes disease.<sup>5</sup> These improved outcomes associated with early diagnosis by measurement of plasma neurochemicals may eventually provide basis for a newborn screening test for Menkes disease in the future.<sup>6</sup>

Our patient's presentation of lightly pigmented hair and recurrent seizures at 2 ½ months of age, together with the history of a brother with similar hair changes and cerebral palsy were important clues to the diagnosis of Menkes disease. However, the correct diagnosis was not made until 11 months of age probably because the management focused mainly on the treatment of the neurologic problem and recurrent pneumonia and that the additional physical features were overlooked. The lack of previous experience in handling actual Menkes disease patients may also be a factor which led to the delay.

Menkes disease is inherited in an X-linked recessive manner. About 1/3 of affected males are de novo cases.<sup>7</sup> The mother was advised regarding the importance of carrier testing since the risk to the proband's siblings depends on her carrier status. However, since there were two affected sons, in the absence of carrier testing, the mother can be assumed as an obligate carrier of the mutation. If no mutation will be found in the mother, germline mosaicism maybe thought of as the possible reason for the presence of the disease in the 2 affected male children.

### Conclusion

Neurologic signs with hair changes and connective tissue abnormalities should alert the clinician for a possible Menkes disease. Subdural bleed, long bone and skull

fracture overlap with child abuse and hence, careful examination is critical. An accurate and early diagnosis is very important in Menkes Disease since copper treatment within the neonatal period had better survival outcomes. Genetic counseling must be part of management due to the risk of recurrence.

### Acknowledgments

We would like to give thanks to **Dr. Stephen G. Kaler** and **Ms. Julia Hicks** of the National Institute of Child Health and Human Development, National Institutes of Health, Bethesda, Maryland, for doing the ATP7A mutation analysis on a charity basis.

### References

1. Datta AK, Ghosh T, Nayak K, Ghosh M. Menkes kinky hair disease: A case report. *Cases J.* 2008; 1(1):158.
2. Tümer Z, Möller LB. Menkes Disease. *Eur J Hum Genet.* 2010; 18(5):511-8.
3. Bacopoulou F, Henderson L, Philip SG. Menkes disease mimicking non-accidental injury. *Arch Dis Child.* 2006; 91(11):919.
4. Ubhi T, Reece A, Craig A. Congenital skull fracture as a presentation of Menkes disease. *Dev Med Child Neurol.* 2000; 42(5):347-8.
5. Kaler SG, Holmes CS, Goldstein DS, et al. Neonatal diagnosis and treatment of Menkes disease. *N Engl J Med.* 2008; 358(6):605-14.
6. Kaler SG, Liew CJ, Donsante A, et al. Molecular correlates of epilepsy in early diagnosed and treated Menkes disease. *J Inherit Metab Dis.* 2010; 33(5):583-9.
7. Kaler SG. ATP7A-Related Copper Transport Disorders. *Gene Reviews [Online].* 2010 [cited 2010 Oct]. Available from <http://www.ncbi.nlm.nih.gov/books/NBK1413/>.