

Ring Chromosome 10 in a Filipino Child: A Case Report and Review of Literature

April Grace Dion-Berboso,^{1,2} Lorna R. Abad,¹ Amelito L. Esquejo² and Mary Anne D. Chiong^{1,2}

¹ Department of Pediatrics, College of Medicine and Philippine General Hospital, University of the Philippines Manila

² Institute of Human Genetics, National Institutes of Health, University of the Philippines Manila

ABSTRACT

We report a 12-day-old infant who presented with ambiguous genitalia, short stature, low-set ears, stubby nose, patent ductus arteriosus and ventricular septal defect. He was confirmed to have a ring chromosome 10 by cytogenetic analysis. Review of the literature showed that our patient shared common clinical manifestations with previously described cases.

Key Words: Ring chromosome 10, cytogenetic analysis, ambiguous genitalia

Introduction

Ring chromosomes are formed when a chromosome undergoes two terminal breaks, followed by fusion of the broken ends or from the union of a broken chromosome with the opposite telomere region, resulting in a ring structure and loss of genetic material.¹ Ring chromosome 10 is a rare cytogenetic abnormality. There have been 11 cases reported in the literature.²⁻¹² Affected patients present with common clinical features which include growth retardation, microcephaly, facial dysmorphism, congenital malformations and learning disability.¹² However, no cases are exactly alike. In this paper, we describe a 12-day-old Filipino male with ring chromosome 10 syndrome and his features were compared to those cases previously described in the literature.

Clinical Report

V. B. is a 12-day-old male, the only child of a non-consanguineous Filipino couple. He was born to a 35-year-old father and 32-year-old primigravid mother who had an uneventful pregnancy. He was delivered full term by caesarian section due to failure of cervical dilatation at a

local hospital. At birth, he was meconium-stained, had fair suck and activity, and was discharged on the second day of life. His birth weight was 2.4 kg (5th percentile). He was initially recognized to be a female with hyperpigmented labia majora but on further examination, absence of vaginal orifice was noted. On the 5th day of life, he was noted to be febrile with poor suck and activity. He was brought to the Philippine General Hospital where he was received in respiratory distress. He was aggressively treated for pneumonia and sepsis, and was investigated for ambiguous genitalia.

Physical examination on the 11th day of life showed that the weight and head circumference were at the 5th percentile and 50th percentile for age, respectively. His length was below the 5th percentile for age. Dysmorphic features that were noted included a stubby nose, small mouth, high-arched palate, prominent occiput, micropenis with hyperpigmented skin around the urethral orifice, and no palpable gonads (Figures 1A and B). Examination of the heart, lungs and abdomen were essentially normal.

Family history revealed that one maternal aunt has Down syndrome and one maternal uncle died at 2 days of age due to a probable congenital heart disease. No other history of chromosomal aberration or malformation was reported.

Investigations for ambiguous genitalia included serum electrolytes which showed normal sodium level at 142 mmol/L but elevated serum potassium at 6.1 mmol/L, thus, congenital adrenal hyperplasia was considered. 17-hydroxyprogesterone (17-OHP) determination done showed elevated levels at 92 nmol/L. However, newborn screening result was normal.

Chest radiography showed infiltrates on both lung fields and cardiomegaly. 2D-echocardiography showed a 2-3 mm muscular VSD and a 2-3 mm PDA.

Cytogenetic investigation done by gross G-banding revealed a 46,XY,r(10)(p12.3q26.3) karyotype wherein breakage and reunion have occurred at bands 10p12.3 and 10q26.3 leading to the formation of a ring chromosome 10. The segments distal to these breakpoints have been deleted (Figure 2).

Corresponding author: April Grace D. Berbos, MD
Institute of Human Genetics
National Institutes of Health
University of the Philippines Manila
625 Pedro Gil Street, Ermita, Manila 1000 Philippines
Telephone: +63917 3259945
Email: aprilgracedion@yahoo.com

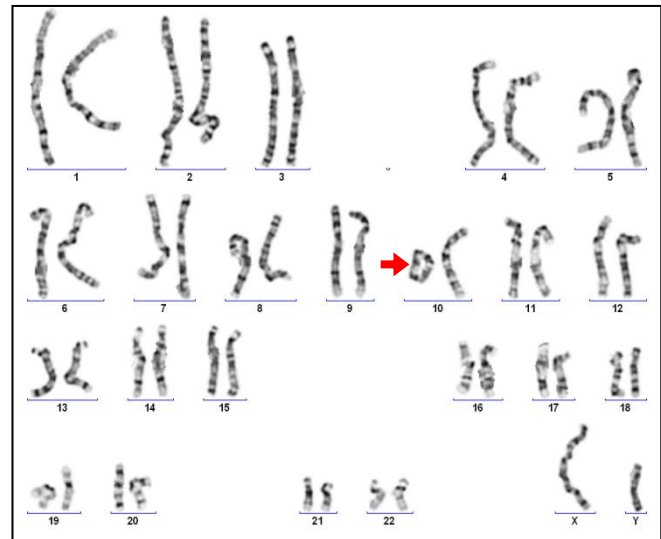
The patient had a stormy clinical course which was marked by electrolyte abnormalities, pneumonia, sepsis and cardiorespiratory failure. On the 12th hospital day, the patient succumbed to septic shock.

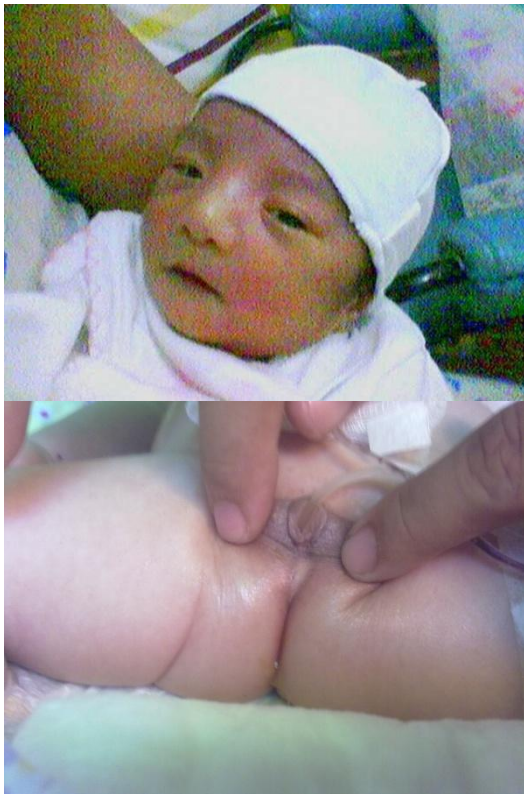

Figure 1 (A and B). The patient had a stubby nose, small mouth, high-arched palate, prominent occiput, micropenis with hyperpigmented skin around the urethral orifice, no palpable gonads (with permission).

Discussion

The evaluation of a newborn with ambiguous genitalia involves investigations that would distinguish congenital adrenal hyperplasia, the most common disorder of sexual development, from other less common causes.¹³ First-line testing in newborns with disorders of sexual development include karyotyping with X- and Y- specific probe detection, abdominopelvic ultrasound, measurement of 17-hydroxyprogesterone, testosterone, gonadotrophins, anti-Mullerian hormone, serum electrolytes and urinalysis.¹⁴ In our patient, investigations showed normal serum sodium, elevated serum potassium, and elevated 17-OHP. The fact that these investigations were taken when the patient was unstable could have led to the elevation of results of potassium and 17-OHP. Ring chromosome 10 is a rare cytogenetic finding with only 11 previously reported cases. These conditions are associated with mental retardation and congenital abnormalities. The previously reported cases of ring chromosome 10 presented with common clinical



46,XY,r(10)(p12.3q26.3)

(Cytogenetics Laboratory, Institute of Human Genetics,
National Institutes of Health, University of the Philippines Manila)

Figure 2. There was breakage in both arms of one chromosome 10 with fusion of the points of fracture and loss of the distal segments leading to ring formation. The breakage and reunion have occurred at bands 10q12.3 and 10q26.3.

features such as mental and growth retardation, low birth weight, microcephaly, stubby nose, hypertelorism, strabismus, wide-set nipples, simple transverse palmar crease, scoliosis, undescended testis, and hypoplastic scrotum.⁸ Our patient presented with short stature, low-set ears, stubby nose, patent ductus arteriosus, ventricular septal defect, and ambiguous genitalia seen as microphallus, undescended testes and hypoplastic scrotum. A review of the 11 previously reported cases together with the present case show common clinical features which include short stature, mental retardation, microcephaly, ocular anomalies such as strabismus and cataracts, stubby nose, congenital heart defects, urinary tract malformation, and undescended testis in males (Table 1).

Male to female sex ratio was 7:5. All patients presented with short stature. Ten out of twelve patients had microcephaly and confirmed mental retardation. Half of the patients showed congenital heart defects, urinary tract abnormalities and a stubby nose. Cardiac defects included interventricular defects, atrial septal defect and patent ductus arteriosus. Abnormalities of the urinary tract included hydronephrosis, and small kidneys. Eight out of twelve patients presented with ocular abnormalities which included strabismus, macular hypoplasia, atrophy of the choroids and small pupils. All 7 male patients had undescended testis. Two of them, including the present case, had micropenis and hypoplastic scrotum (Table 1).

Table 1. Comparison of the anomalies found in cases of ring chromosome 10.

Feature	Lansky et al. (1979)	Fryns et al. (1978)	Sparkes et al. (1978)	Simoni et al. (1979)	Tsakino et al. (1980)	Michels et al. (1981)	Serville et al. (1982)	Nakai et al. (1983)	Kondo et al. (1984)	Kishi et al. (1985)	Gunnarson et al. (2009)	Present case	Total
Sex	F	M	F	M	F	M	F	M	M	M	F	M	7:5
Short stature	+	+	+	+	+	+	+	+	+	+	+	+	12/12
Short neck	-	+	-	-	-	-	...	-	-	-	+	+	3/12
Mental retardation	+	+	+	+	+	+	+	+	+	+	10/12
Microcephaly	+	+	+	+	+	+	...	+	+	+	+	-	10/12
Prominent nasal bridge	-	+	-	-	-	+	...	-	+	-	+	-	3/12
Stubby nose	-	-	-	-	+	+	...	+	+	-	+	+	6/12
Low set ears	-	-	+	-	-	+	...	+	-	-	+	-	4/12
Ocular abnormalities	-	-	+	+	+	+	+	+	+	-	+	-	8/12
Widely spaced nipples	+	+	-	+	-	-	...	+	-	-	+	-	5/12
Congenital heart defects	+	+	+	-	-	-	...	-	-	+	+	+	6/12
Urinary tract malformation	-	-	+	+	+	+	+	-	+	-	-	...	6/12
Undetectable or undescended testis	NA	+	NA	+	NA	+	NA	+	+	+	NA	+	7/7
Micropenis	NA	-	NA	-	NA	-	NA	+	-	-	NA	+	2/7
Hypoplastic scrotum	NA	-	NA	-	NA	-	NA	+	-	-	NA	+	2/7
Other abnormalities	Pectus excavatum	Hypotonia, short upper lip, microretrognathism, high-arched palate with bifid uvula, large tongue, broad thorax, thizomelic shortening of extremities, rocker-bottom feet	Estrogenized external genitalia, increased angles of arms, syndactyly between second and third toes	Hypotonia, Simian crease	Antimongoloid slant, protruding ears, erythrocyanosis, edema and pigmentation of both feet	Persistent pulmonary hypertension	Simian crease	Hypertelorism, pointed chin	Photo-hyper-sensitivity	Small mouth with thin lips, webbed neck, clinodactyly of the fifth finger, malformed rocker-bottom feet	Prominent occiput, talipes equinovarus		

Legend : ... - No data available; NA - Not applicable

The most common breakpoints, presenting in 9 out of 12 patients, are in 10p15 and 10q26. However, no cases are exactly alike. The variability in the phenotypes may be due to variations in the break points, amount of deleted material, and degree of mosaicism for cells lacking the ring chromosome.^{2,10} Our case presents with almost similar clinical features to the case reported by Nakai et al.⁹ Both patients presented with short stature, stubby nose, undescended testis, micropenis, and hypoplastic scrotum.

Features found in ring chromosome syndromes often overlap with the features of terminal deletion for the corresponding chromosome.¹⁵ Our patient had a set of features similar to that seen in patients with 10q26 deletion syndrome which include small penis, cryptorchidism, and hypoplastic scrotum.^{16,17} Terminal deletion of 10q appears to include some genes indispensable for normal male genital development which may explain the genital abnormalities seen in the patients.¹⁷ In fact, a genotype-phenotype correlation study done by Ogata et al. using microsatellite analysis in patients with distal 10q monosomy, suggested that novel gene(s) involved in urinary and genital development reside in 10q26, specifically in the regions distal to D10S186 and D10S1248, respectively.¹⁸

About 99% of ring chromosomes arise sporadically. However, some persons with a ring chromosome seem to be of normal phenotype with reproductive potential.¹⁹ Thus, doing chromosomal analysis on both parents is recommended to check for carrier status and to be able to predict probability of recurrence in future offsprings.

Conclusion

At present, no specific features are found to help make a clinical diagnosis of ring chromosome 10. However, it can be seen that the affected patients present with common clinical features such as short stature, mental retardation, facial dysmorphism and genital abnormalities, which in the future, may be used to delineate the syndrome. It is worthy to note that ring chromosome 10 patients have features overlapping with that of deletion 10q syndrome. Microarray analysis is recommended to be able to determine the genes lost in the ring chromosome formation, study their functions, and do phenotypic correlations.

References

- Sodre CP, Guilherme RS, Meloni VF, et al. Ring chromosome instability evaluation in six patients with autosomal rings. *Genet Mol Res.* 2010; 9 (1):134-43.
- Lansky S, Daniel W, Fleiszar K. Physical retardation is associated with ring chromosome mosaicism: 46,XX, r(10)/45, XX,10-. *J Med Genet.* 1977; 14(1):61-3.
- Fryns JP, De Boeck K, Jaeken J, van den Berghe H. Malformative syndrome associated with a ring 10 chromosome and a translocated 10q/19 chromosome. *Hum Genet.* 1978; 43(2):239-44.
- Sparkes RS, Ling SM, Muller H. Ring 10 chromosome: 46,XX, r10(p15q26). *Hum Genet.* 1978; 43(3):341-5.
- Simoni G, Rossella F, Dalpra L, Visconti G, Piria-Schwarz C. Ring chromosome 10 associated with multiple congenital malformations. *Hum Genet.* 1979; 51(2):117-21.
- Tsukino R, Tsuda N, Dezawa T, Ishii T, Koike M. Ring chromosome 10: 46,XX,r(10)(p15→q26). *J Med Genet.* 1980; 17(2):148-50.
- Michels VV, Driscoll DJ, Ledbetter DH, Riccardi VM. Phenotype associated with ring 10 chromosome: report of patient and review of literature. *Am J Med Genet.* 1981; 9(3):231-7.
- Serville F, Briault R, Taillemite JL, Despoisse S, Cotoni P, Broustet A. [Ring chromosome 10: 46,XX,r(10)(p15q26)]. *Ann Genet.* 1982; 25(3):168-71.
- Nakai H, Adachi M, Katsushima N, Yamazaki N, Sakamoto M, Tada K. Ring chromosome 10 and its clinical features. *J Med Genet.* 1983; 20(2):142-4.
- Kondo I, Shimakura Y, Hirano T, Kaneko M, Yabuta K. Ring chromosome 10 syndrome: case report and the possibility of clinical diagnosis. *Clin Genet.* 1984; 25(2):196-200.
- Kishi K, Ikeuchi T, Yamamoto K, Tonomura A, Sakurada N, Satoh Y. Report of a patient with a ring chromosome 10: mos45,XY,-10/46,XY/46,XY, r(10)(p15.3q26.3). *Jinrui Idengaku Zasshi.* 1985; 30(3):233-8.
- Gunnarson C, Graffmann B, Jonasson J. Chromosome r(10)(p15.3 q26.12) in a newborn child: case report. *Mol Cytogenet.* 2009; 2:25.
- Medscape, Ambiguous Genitalia and Intersexuality [Online]. 2009 [cited 2010 Aug]. Available from <http://emedicine.medscape.com/article/1015520-overview>.
- Lee PA, Houk CP, Ahmed SF, Hughes IA. Consensus statement on management of intersex disorders. *Pediatrics.* 2006; 118(2):e488-500.
- Knijnenburg J, van Haeringen A, Hansson KB, et al. Ring chromosome formation as a novel escape mechanism in patients with inverted duplication and terminal deletion. *Eur J Hum Genet.* 2007; 15(5):548-55.
- Tanabe S, Akiba T, Katoh M, Satoh T. Terminal deletion of chromosome 10q: clinical features and literature review. *Pediatr Int.* 1999; 41(5):565-7.
- Suzuki Y, Sasagawa I, Nakada T, Onmura Y. Bilateral cryptorchidism associated with terminal deletion of 10q. *Urol Int.* 1998; 61(3):186-7.
- Ogata T, Muroya K, Sasagawa I, et al. Genetic evidence for a novel gene(s) involved in urogenital development on 10q26. *Kidney Int.* 2000; 58(6):2281-90.
- Gardner RJM, Sutherland GR. Chromosome abnormalities and genetic counseling. New York: Oxford University Press Inc., 2004.